

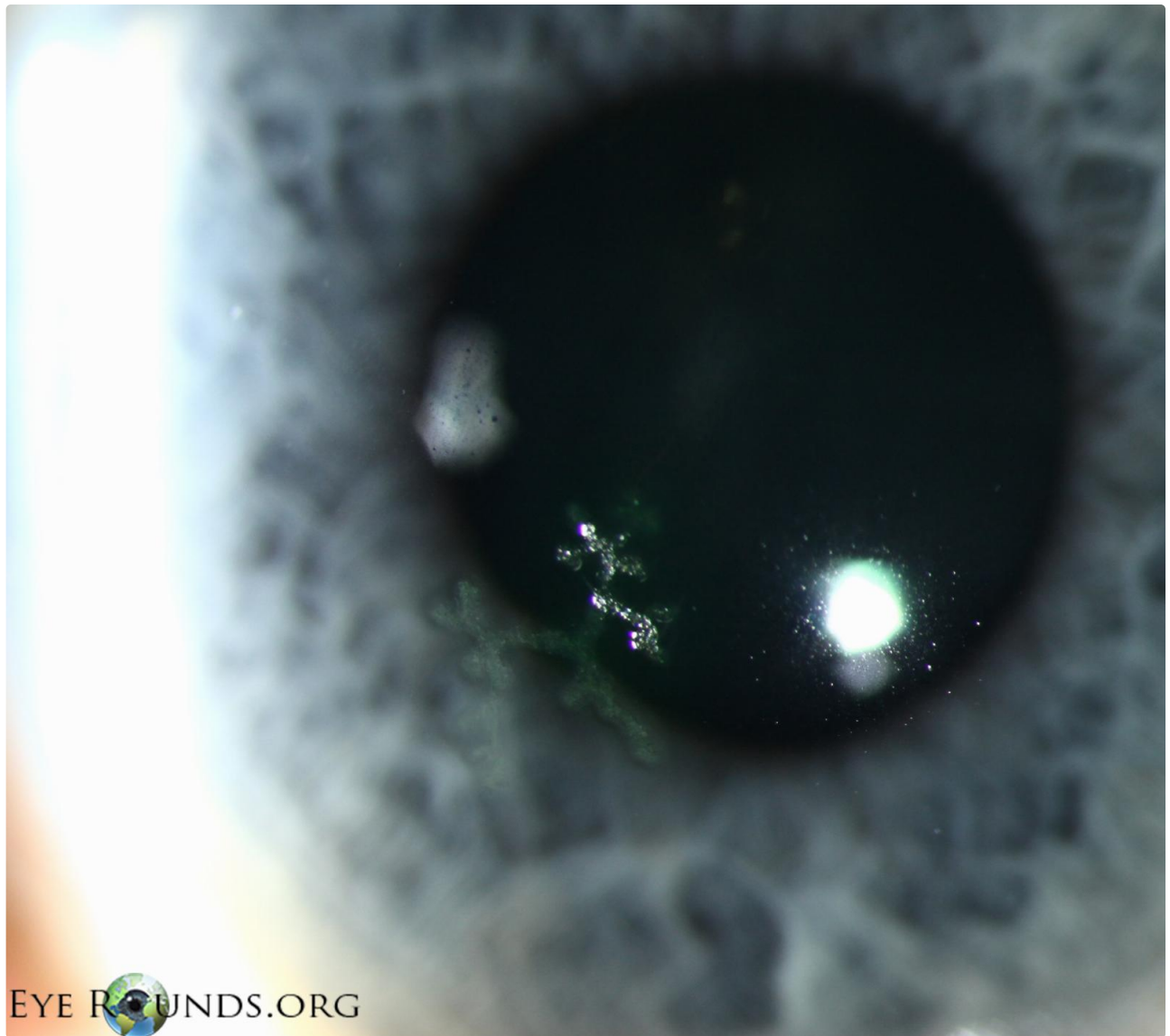## Herpes simplex virus (HSV) epithelial keratitis, dendrite

Category(ies): Cornea

Contributor: [Jesse Vislisel, MD](#)

Photographer: Carol Chan, CRA

Dendritic ulcers are the classic lesion associated with herpes simplex virus (HSV) epithelial keratitis. This photograph portrays the typical appearance of these ulcers - swollen epithelium along the margins of a positive-staining, dendritic corneal ulcer with terminal bulbs at the ends of the branches. This contrasts with the appearance of [Varicella-zoster virus \(VZV\) pseudodendrites](#).



EyeRounds.org

HSV-dendrite

 Enlarge

 Download

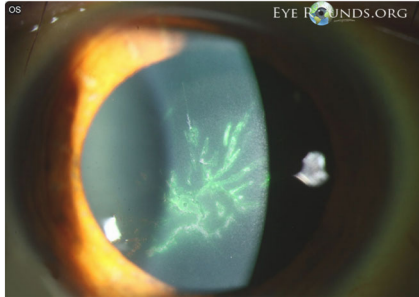
## Image Permissions:



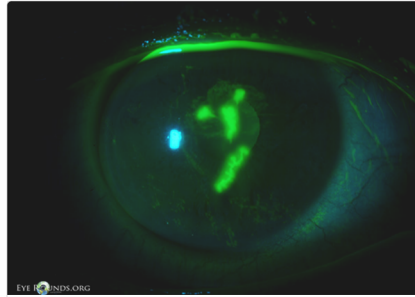
Ophthalmic Atlas Images by [EyeRounds.org](https://www.eyerounds.org), [The University of Iowa](https://www.eyerounds.org) are licensed under a [Creative Commons Attribution-NonCommercial-NoDerivs 3.0 Unported License](https://creativecommons.org/licenses/by-nc-nd/3.0/).



## Related Articles



[Related Atlas Entry: Varicella-zoster virus \(VZV\) epithelial keratitis, pseudodendrites](#)



[Related Case: Herpes Simplex Keratitis](#)

## Address

University of Iowa  
Roy J. and Lucille A. Carver College  
of Medicine  
Department of Ophthalmology and  
Visual Sciences  
200 Hawkins Drive  
Iowa City, IA 52242

[Support Us](#)

## Legal

Copyright © 2019 The University of  
Iowa. All Rights Reserved  
[Report an issue with this page](#)  
[Web Privacy Policy](#) |  
[Nondiscrimination Statement](#)

## Related Links

[Cataract Surgery for Greenhorns](#)  
[EyeTransillumination](#)  
[Gonioscopy.org](#)  
[Iowa Glaucoma Curriculum](#)  
[Iowa Wet Lab](#)  
[Patient Information](#)  
[Stone Rounds](#)  
[The Best Hits Bookshelf](#)

## EyeRounds Social Media

Follow



[Receive notification of new cases,  
sign up here](#)  
[Contact Us](#)  
[Submit a Suggestion](#)